



Plant Archives

Journal homepage: <http://www.plantarchives.org>
doi link : <https://doi.org/10.51470/PLANTARCHIVES.2021.v21.S1.126>

EVALUATION OF THE EFFICACY OF GARLIC NANOPARTICLES TO MINIMIZE ATHEROGENIC ACTIVITY INDUCED BY A TRITON AND HIGH FAT CONSUMPTION IN ADULT MALE RATS.

Sarah I.K.AL-Anawe and Hayder A.N.AL-Zamely

Department of Veterinary Physiology, College of Veterinary, Medicine, AL-Qasim Green University, Babylon. Iraq.

*Email:sarah20162811@gmail.com

ABSTRACT

This study was carried out at the Animals House, College of Veterinary Medicine, AL-Qasim Green University, for the period between October 2019 to January 2020 to find out the effect of garlic extract and its nanoparticles to improve the performance of the cardiovascular system in adult male rats who were exposed to cholesterol (0.5 ml), H₂O₂ for four weeks and single dose of triton x100 was intraperitoneal administrated at the end of third weeks. A total of (75) adult male albino rats were used in the present study, at the age of 2 months with body weight 195±15gm were divided randomly to five equal groups (15 rats for each) and treated as follow :-Control group :- animals in this group still normal without any treatment as negative control. First group (T1): animals in this group was induced atherosclerosis and treated with daily dose 35.4mg/kg of nanoparticles garlic given orally by stomach tube. Second group (T2): animals in this group was induced atherosclerosis and treated with daily dose 35.4mg/kg of extract garlic given orally by stomach tube. Third group (T3): animals in this group still normal (no atherogenic) but treated with daily dose 35.4mg/kg of nanoparticles garlic given orally by stomach tube. Fourth group (T4): animals in this group was induced atherosclerosis and treated with distal water as positive group. at the end of the experiment all animals were sacrificed and blood samples were collected directly from heart puncture and serum samples were isolated to estimate of, glucose concentration, C-reactive protein, and samples from aorta taken for histological study. The effect of garlic (nanoparticles and extract) on Glucose concentration showed that (T1) rats received orally garlic nanoparticles showed a significant reduction under ($P < 0.05$) to when compared among other treated groups involve positive control rats. Effect of garlic (nanoparticles and extract) on C reactive protein (CRP) a significant elevation in serum CRP specially in positive control group (T4) and rats in group (T2) that received extract of garlic as well as there is no a significant difference between them. Histopathological section of atherogenic rats received 35.4mg/kg garlic nanoparticales revealed The right side of the artery has a fairly normal appearance but a hyperplastic lesion has evolved on the left side. On the other aspect garlic extract revealed normal thickening of arterial wall except mild hyperplasia in the right side of artery the lumen of artery showed wide. The present study concluded that garlic nanoparticle improvement of glucose and CRP as well as regeneration of tissue aorta that maybe become as promise treatment for resolve the cardiovascular problems in future.

Keyword: Atherosclerosis, garlic, nanoparticles, aorta, CRP

Introduction

Atherosclerosis is a chronic inflammatory condition, atherosclerotic dysfunction, Plaque Rupture, vascular stenosis, or occlusion caused by accumulation of platelets and thrombosis contribute to acute cardiovascular diseases. Inflammation associated with atherosclerosis is mediated by pro-inflammatory cytokines, inflammatory signalling pathways, bioactive lipids, and adhesion molecules (Mihaylova *et al.*, 2016). Atherosclerosis results from endothelial damage to the artery caused by environmental and mechanical factors, resulting in an inflammatory reaction in the wall of a vessel (Hansson *et al.*, 2006). Atherosclerosis is a disease involves large arteries where these blood vessels to become hard on account of to the precipitation of a fatty material known such as cholesterol. This precipitation and hardening in giving rise to disturb the normal physiological function of the affected vessels and cause a major risk factor of heart diseases and stroke, Endothelial dysfunction, vascular inflammation, lipid accumulation, cholesterol and

calcium, inflammatory cells, matrix deposit and smooth muscle cell proliferation And cellular debris inside the vessel wall intima (Jellinger *et al.*, 2017; Lacolley *et al.*, 2017).

American Heart Association (AHA) reported that more than 17 million people died in 2013 due to cardiovascular disease, representing the first etiology of death in the world (Mozaffarian *et al.*, 2016) The etiology of CVD is very complex, and one of the main pathogenic factors is overproduction of oxidants. Oxidative damage can cause injury to the endothelial cells and harmful The consequences of vasodilators. It has been demonstrated that antioxidant polyphenols can alter molecular events to enhance endothelial function and thus play an important role in CVD prevention (Prahalthan *et al.*, 2012).

Literature evidence On the effects of food and bioactive compounds it has been shown that some nutrients and components of food may have a beneficial influence On lipid profiles (monounsaturated and polyunsaturated fatty acids,

soluble fibres, vegetable proteins, phytosterols and polyphenols) (Rosa *et al.*, 2015). A balanced Effective control and lipid profile regulation was correlated with vegetables and fruits (Fidanza *et al.*, 2004). To prevent hyperlipidemia which includes Natural antioxidants. Compounds which lower lipids, found Can be used in food supplements and medicinal plants beneficial for lipid By Metabolism affecting Metabolization processes For different tissues, and of certain lipid-lowering properties have been due in most cases to their antioxidant properties, at least in part (Bahmaniet *al.*, 2015). Also, polyphenols could protect the cardiovascular system not only from oxidative stress but also from other damage because they have other physiological effects, such as reducing blood pressure and decreasing inflammation (Prahalthan *et al.*, 2012). Nanoparticle therapeutics has attracted rising attention in recent years as an emerging treatment modality in cancer 11 and other inflammatory disorders (Zhang *et al.*, 2016, Boisgard *et al.*, 2017). The study aimed to using garlic nanoparticales in treatment of atherosclerosis. Preparation of nanoparticles to overcome the side effects of ordinary garlic. To study cytogenic effect of garlic (nanoparticles and extract) on atherosclerosis induced in rats.

Materials and Methods

Preparation of garlic nanoparticales

Garlic nanoparticales were synthesis by chemical reaction a sit reported in several articles with 2gm/100ml extract is dissolved in deionized water in order to formulate and heated for 1hour at 60 on magnetic stirrer and adding 2% acetic acid (Hamza AM., 2019).

Experimental animals

The study was performed in the Animal house of the Veterinary College of Medicine / University of Al-Qasim Green for the period between October 2019 to January 2020. A total of (75) adult male albino rats were used in the present study, About 2 months ago and high body weight 195±15gm. Animals were kept in the animals house of Veterinary College, AL-Qasim Green University, and divided randomly into five groups (15 each) treated as follow :- Control group :- animals in this group still normal without any treatment like negative control. First group (T1): this group have animals was induce atherosclerosis and treated with daily dose 35.4mg/kg of nanoparticles garlic given orally by stomach tube. Second group (T2): this group has animals was induced atherosclerosis and treated with daily dose 35.4mg/kg of extract garlic given orally by stomach

tube. Third group (T3): animals in this group still normal without infection but treated with daily dose 35.4mg/kg of nanoparticles garlic given orally by stomach tube. Fourth group (T4): animals in this group was induced atherosclerosis and treated with distal water as positive group. Finally the experiment was persistent for 12 weeks. Serum were collected at the end of study to determine Lipid profile (TG, TC, LDL and HDL). Moreover ,animals were anesthetized with ketamine (80 mg / kg) and xylazine (12 mg / kg) for isolation of tissue for evaluation histopathological study on the blood vessel (aorta tissue) were prepared on microscopic slides.

Statistical analysis

Data were analyzed for the treatments of each trait by using computer program (SPSS), Version 23 one-way analysis of variance (ANOVA) were used, least significant difference (LSD) among different group means at 5% level was applied (Joda, 2008).

Results and Discussion

Effect of garlic (nanoparticals and extract) on Glucose concentration:

The present study in table (4-2) showed that (T1) rats received orally garlic nanoparticles showed a significant reduction under (P <0.05) to recorded mean value (199.60±9.8) when compared with other groups involve positive control rats (T4) and received garlic extract (T2) , as well as that received normal diet with nanoparticles of garlic, all above group showed there is no a significant difference between them under (P <0.05) to the randomly serum glucose concentration to recorded mean value (236.90 ± 15.94 , 233.90 ±10.92 and 235.20 ± 16.09) respectively. The present study was agreement with (Eidi *et al.*, 2006) who reported that garlic extract (*Allium sativum* L.) was administrated to healthy and diabetic rats showed significantly decreased serum glucose, lipid profiles, urea, uric acid, creatinine, AST and ALT levels, while increased serum insulin in diabetic rats but not in normal rats (p<0.05) as well as garlic extract more beneficial effect than glibenclamide. The Nano suspensions of garlic are best method for enhancing solubility and bioavailability, increasing plasma half-life, and eventually improving the efficacy of these natural compounds in garlic for management of blood glucose. Different natural-based nan formulations have shown promising effect in treatment of diabetes and atherogenic instead of pharmaceutical drugs if they pass clinical trials successfully (Taghipour *et al.*, 2019).

Table 1 : Show the effect of high cholesterol 0.5ml as hydrogen peroxide 0.5% accompanied by a single dose of triton at end of three weeks and treated with garlic (extract, nanoparticals) on glucose concentration and CRP.

Parameter	CRP		G con
	B.T	A.T	A.T
CONTROL	0.31 ±0.16 d	0.31 ±0.16 b	271.60 ±7.11 a
T1	3.94 ±0.02 a	0.54±0.12 b	199.60 ±9.88 c
T2	3.06±0.24 B	3.92 ±0.58 a	236.90 ±15.94 b
T3	0.81 ±0.02 C	0.036 ±0.01 b	233.9 ±10.92 B
T4	4.12 ±0.34 A	4.03 ±0.39 a	235.20 ±16.04 b
LSD	0.215	0.34	13.02

The value represents mean ± SE, N=15 for each group
Different capital letters indicate significant (P < 0.05) among groups.

Effect of garlic (nanoparticles and extract) on C reactive protein(CRP)

The animals that treated with a high cholesterol 0.5 ml as hydrogen peroxide 0.5% accompanied by a single dose of triton at end of three weeks reported a significant elevation in serum CRP specially in positive control group (T4) and rats in group (T2) that received extract of garlic as well as there is no a significant difference between them under ($P < 0.05$) to recorded mean value (4.03 ± 0.39 and 3.92 ± 0.58) respectively. Our data revealed there is no significant difference under ($P < 0.05$) between negative control group when compared with rats induced atherosclerosis and treated with *Allium sativum* no particles (T1) and garlic no particles that administrated to animal in (T3) that still has normal value of serum to recorded value (0.31 ± 0.16 , 0.54 ± 0.12 AND 0.36 ± 0.01) respectively. C-reactive protein (CRP) is one of the strongest predictors for the risk of cardiovascular events and atherosclerosis. The elevation of serum CRP in hyperlipidemia rats was agreement with many studies that

Histopathological study

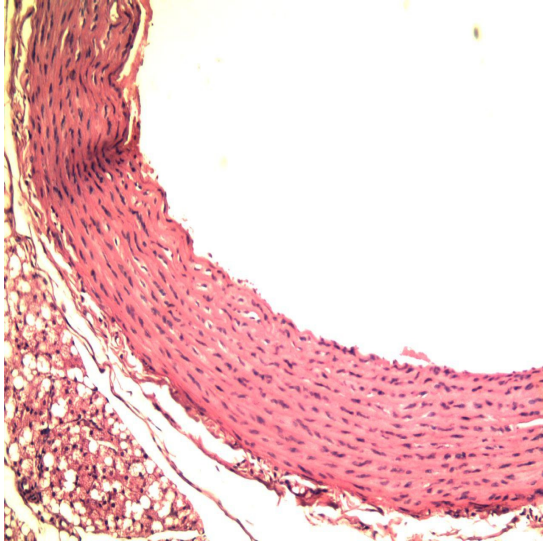


Fig. 1 : Negative control group show: There is normal endothelial cells which lining intima, and normal smooth muscle fibers with normal nuclei.

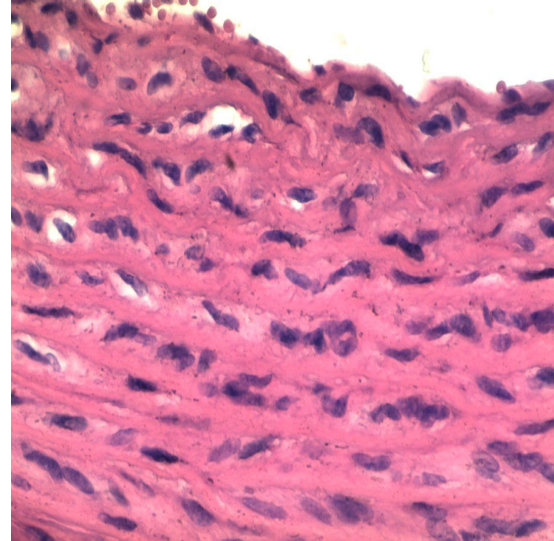


Fig. 2 : Negative control group show :Higher magnification, there is normal endothelial cells with normal smooth muscle fibers which showed normal arrangement with normal nuclei.

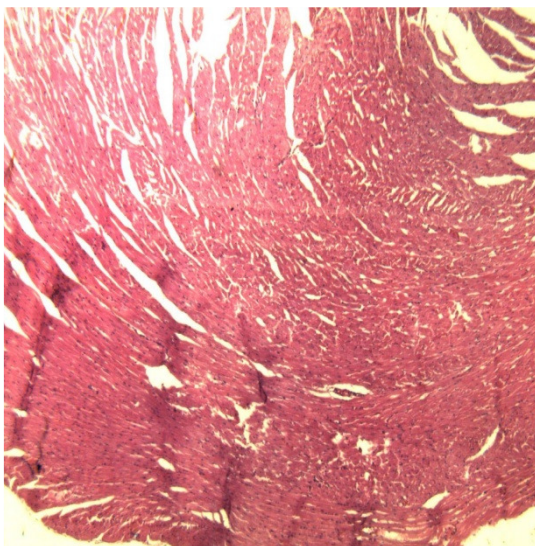


Fig. 3 : Histopathological section of atherogenic rats (T1) : show Internal thickening with degeneration in the smooth muscle cells and congestions among the smooth muscle fibers.

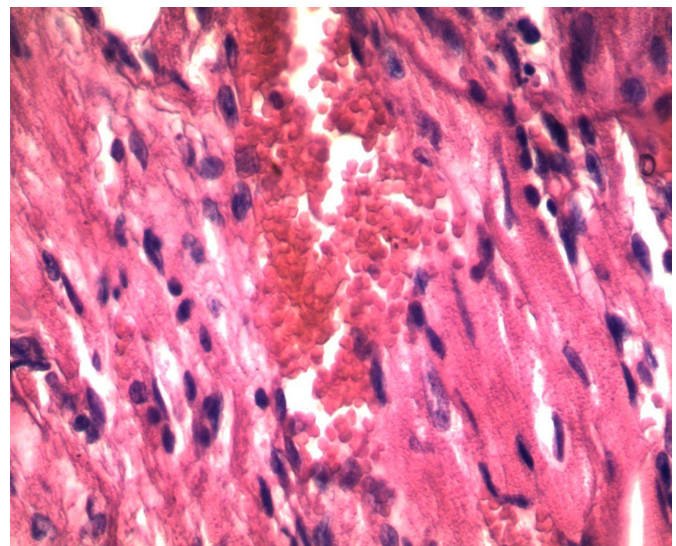


Fig. 4 : Histopathological section of atherogenic rats ((T1) : show marked hemorrhage in the media and infiltration of foamy cells.

refer (Torzewskiet *al.*,2014 ; Papapanagiotou *et al.*,2015). Numerous studies in vitro have reported the capacity of garlic extract to minimize parameters related with cardiovascular events. CRP directly participates in the progress of atherogenesis by modulating endothelial. On the other hand raise level of serum CRP has been related with insulin resistance syndrome so that our result reported elevation of serum glucose. Zareetal (2019) confirmed The rates of IL-6 and CRP dramatically increased in the garlic-treated community at the end of the two-month cycle. The garlic can minimize inflammatory markers CRP so that can improve cardiovascular health, study was agreement with (Leeet *al.*,2015) who reported that in-vitro study, a significant reduction in Tumor TNF- α , IL-1 α , IL-6, IL-8, T-cell interferon-gamma (IFN- π), and IL-2 due to sulfur-containing garlic compounds include Z- and E-ajoene and oxidized ajoenesulfonyl derivatives which inhibit the expression of pro-inflammatory cytokines such as tumor necrosis factor- α , IL-1 β , and IL-6.

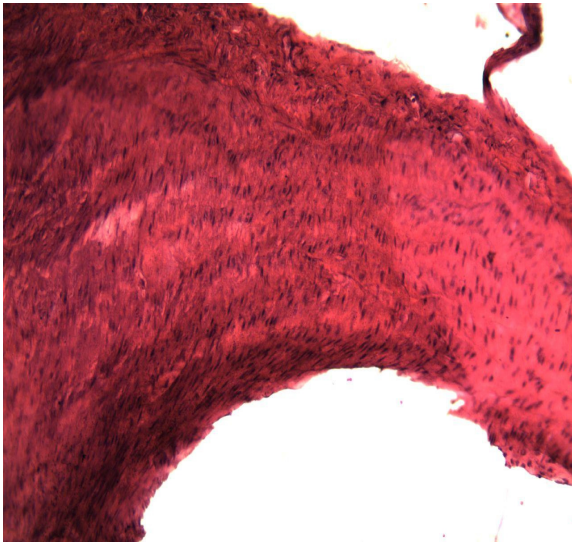


Fig. 5 : Histopathological section of atherogenicratsG(1):treated with 35.4mg/kg garlic nanoparticules revealed Marked hyperplasia of smooth muscle fibers with mild foamy cells in media layer of artery.

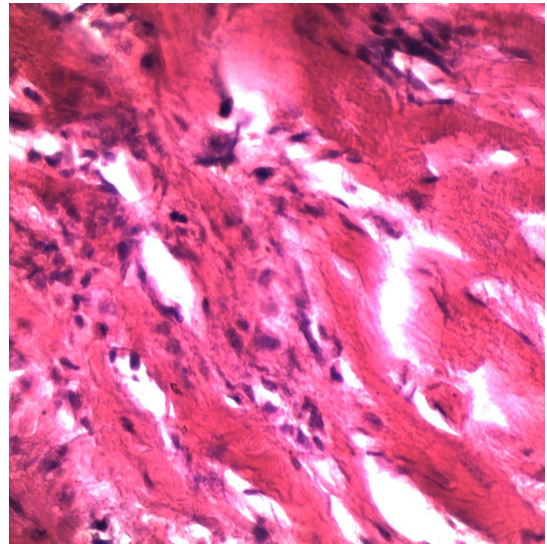


Fig. 6 : Histopathological section of atherogenic rats G(1):treated with 35.4mg/kg garlic nanoparticules revealed Higher magnification, mild infiltration of inflammatory cells mainly foamy cells in the media layer of artery.

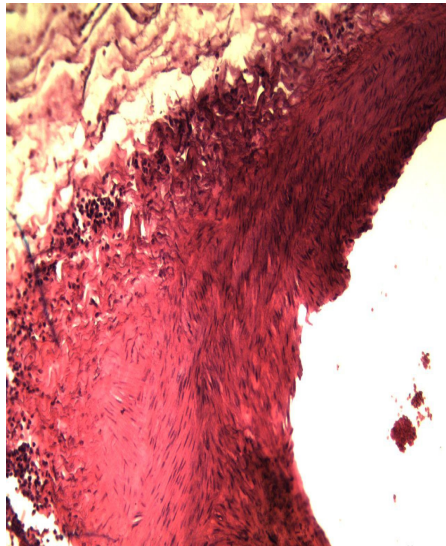


Fig. 7 : Histopathological section of atherogenicratsG(2):treated with 35.4mg/kg garlic extract revealed Mild hyperplasia of smooth muscle fibers with normal endothelial cells which lining intima. also there is few infiltration of inflammatory cells mainly macrophages and foamy cells.

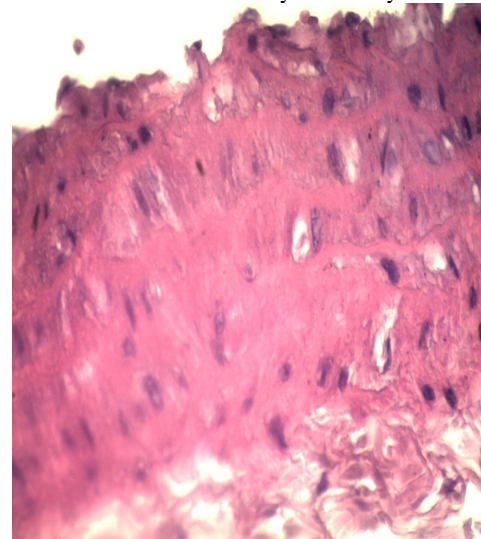


Fig. 8 : Histopathological section of aorta tissue G(3):treated with 35.4mg/kg garlic nanoparticules revealed Higher magnification, normal endothelial cells which lining intima and normal arrangement of smooth muscle fibers with normal elongated nuclei(normal)

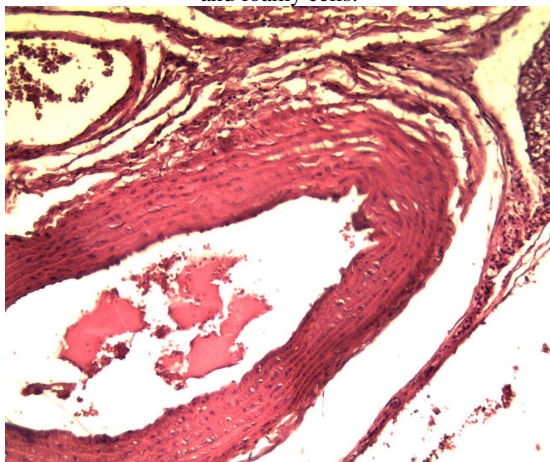


Fig. 9 : Histopathological section of aorta tissue G(3):treated with 35.4mg/kg garlic nanoparticules revealed Normal arterial wall (normally arrangement of smooth muscle fibers) with wide lumen.

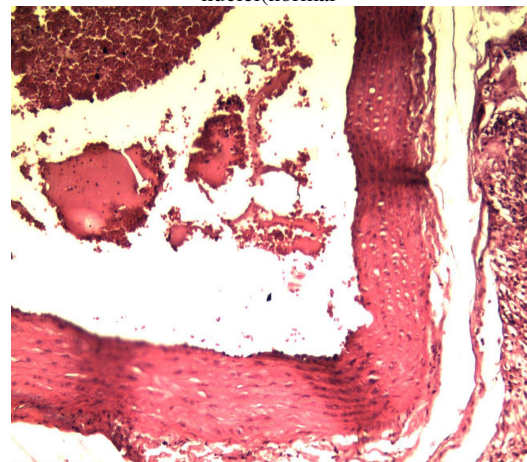


Fig. 10 : Histopathological section of aorta tissue G(3):treated with 35.4mg/kg garlic nanoparticules revealed Normal endothelial cells which lining intima, and normal arrangement of smooth muscle fibers.

Aorta tissue

Histopathological section of atherogenic rats that received nanoparticles of garlic (T2) reported in figure (3,4) showed there is thickening and hyperplasia of smooth muscle fibers with infiltration of inflammatory cells and amyloid degeneration in the media and degeneration of smooth muscle fibers with infiltration of inflammatory cells particularly foamy cells. Our result was agreed with (Pashaie *et al.*, 2017; Jasimet *et al.*, 2020) that reported there is an increase in aortic wall diameter after chronic consumption of a cholesterol, H₂O₂ with thickness and irregularity of medial and internal elastic lamina. Furthermore, this result may be attributed to H₂O₂ with high fat lead to persistent accumulation of platelets and macrophages resulted in proteolytic destruction of the aortic architecture via release of Matrix metalloproteinases (MMPs) as well as, lead to lipid peroxidation of LDL by free radicals like hydrogen peroxide results in negative influence On vascular function such as reduction of the levels of nitric oxide (NO), endothelial apoptosis, increment of smooth muscle cell proliferation, and synthesis of pro-inflammatory cytokines such as TNF- α and had counteracting roles in intimal thickening and stabilizes plaques, on the one hand extracellular matrix destruction that leads to plaque rupture (Mastenbroek *et al.*, 2014; Newby, 2015; Abdou *et al.*, 2018).

Histopathological section of atherogenic rats G treated with 35.4mg/kg garlic extract revealed Mild hyperplasia of smooth muscle fibers with normal endothelial cells which lining intima. also there is few infiltration of inflammatory cells mainly macrophages and foamy cells.

Histopathological section of our result was concord with Gonen *et al.*, (2005) that reported that pure allicin, reduced atherosclerosis in mice due to potent antioxidant as well as modify lipoprotein with Inhibition of LDL absorption and macrophage degradation. Saponins have been shown to have the benefits of antioxidation, antiplatelet aggregation, vasodilation and reduction of blood lipids, and offer a possible new natural source of cardiovascular disease prevention and treatment (Singh and Chaudhuri, 2018). Garlic has been contain saponin, that has role to reduced atherosclerotic by inhibit plaque formation that responsible for progression of atherosclerotic disease. The recent reported by Miao *et al.*, (2020) concluded that total saponin garlic restored the serum lipid profile and reduced malondialdehyde (MDA), as well as elevated superoxide dismutase (SOD) maintain the ratio of thromboxane B2 (TXB2) and 6-keto-prostaglandin F1 α (6-keto-PGF1 α) that required for vascular homeostasis. TXA2 induces vasoconstriction and platelet accumulation and promotes development of atherosclerosis, so that antiplatelet effect of garlic may be potentiate PGI2 has the function to inhibiting platelet aggregation and vasodilation 36]. In fact, the equilibrium between PGI2 and TXA2 plays a crucial role in preventing and managing atherosclerosis by preserving the essential structure of the blood vessels and platelets (Olschewski *et al.*, 2004; Fan *et al.*, 2018).

Histopathological section of aorta tissue from atherogenic rats received 35.4mg/kg garlic nanoparticale showed normal endothelial cells which lining intima and normal arrangement of smooth muscle fibers with normal elongated nuclei(normal media). Moreover normal arterial wall with wide lumen was noted in figure (5,6). The

formation of nanoparticles, nanoemulsions and nanocapsules can improve the functional properties of the garlic extract and increasing their absorption from GIT due to increase surface area and small particles easily penetrate to gut wall and reach to blood stream as well as easily enter to intra cellular and accumulated at target tissue for long period of time (Twegh *et al.*, 2020). (Trujillo *et al.*, 2013) and many researcher that suggest that advantages of NPs are improved bioavailability and multiple drugs loaded in a single nanocarriers, therapeutic efficacy; enhanced shelf-life, improved solubility of poorly water-soluble or drug extract, reduced demand dose that aid to reduce toxicity, and small size aid to elevating uptake of active compound by tissue at target of action so that increase affinity as well as efficacy (Singh, 2017; Worrall *et al.*, 2018).

On the other new suggest mechanism that clear prominent in histopathological of aorta tissue section may be due to reduced pro-inflammatory cytokines (TNF α and IL6) and enhancement activity anti-inflammatory cytokines (IL10) that was demonstrated (Makris and co workers, 2005) that IL-10 as potently antiatherogenic as well as diminished atherosclerotic plaque burden, and limitation infiltrated inflammatory cell to plaque, thus (Sabat *et al.*, 2010) reported that IL10 reduced and confirm that IL-10 – deficient C57BL/6J mouse fed an atherogenic diet and demonstrated a significant 3-fold excess in fat accumulation compared with wild-type mouse.

Conclusions

The present study concluded that garlic nanoparticle improvement of glucose and CRP as well as regeneration of tissue aorta via, normal endothelial cells which lining intima and normal arrangement of smooth muscle fibers with normal elongated nuclei.

References

- Bahmani, M.; Mirhoseini, M.; Shirzad, H.; Sedighi, M.; Shahinfard, N.; and Rafieian-Kopaei, M. (2015). A review on promising natural agents effective on hyperlipidemia. *Journal of Evidence-Based Complementary and Alternative Medicine*, 20(3), 228–238.
- Boisgard, A. S.; Lamrayah, M.; Dzikowski, M.; Salmon, D.; Kirilov, P.; Primard, C.; and Verrier, B. (2017). Innovative drug vehicle for local treatment of inflammatory skin diseases: Ex vivo and in vivo screening of five topical formulations containing poly (lactic acid) (PLA) nanoparticles. *European Journal of Pharmaceutics and Biopharmaceutics*, 116: 51-60.
- Fan, H.; Li, M.; Yu, L.; Jin, W.; Yang, J.; Zhang, Y.; & Wan, H. (2018). Effects of Danhong injection on platelet aggregation in hyperlipidemia rats. *Journal of ethnopharmacology*, 212: 67-73.
- Fidanza, F.; Alberti, A.; Lanti, M.; and Menotti, A. (2004). Mediterranean Adequacy Index: correlation with 25-year mortality from coronary heart disease in the Seven Countries Study. *Nutrition, Metabolism and Cardiovascular Diseases*, 14(5).
- Gonen, A.; Harats, D.; Rabinkov, A.; Miron, T.; Mirelman, D.; Wilchek, M.; ... & Shaish, A. (2005). The antiatherogenic effect of allicin:

- possible mode of action. *Pathobiology*, 72(6): 325-334.
- Hamza, A.M.; Liks, A.; and Alhtheal, A.D. (2019). Synthesis and characterization of chitosan/EDTA/PVA nanofiber of Antimicrobial Application. *Journal of Global pharimatechnology* 11(7): 453-459.
- Hansson, G.K.; Robertson, A.-K. L. and Söderberg-Nauclér, C. (2006). Inflammation and atherosclerosis. *Annu. Rev. Pathol. Mech. Dis.*; 1, 297-329.
- Jasim, A.M.; Hasan, H.F. and Awady, M.J. (2019). Preparation of Vorapaxar loaded with Vitamin E TPGS and PVA emulsified PLGA nanoparticles In vitro studies. *Research Journal of Pharmacy and Technology*, 12(9): 4503-4510.
- Jellinger, P.S.; Handelsman, Y.; Rosenblit, P.D.; Bloomgarden, Z.T.; Fonseca, V.A.; Garber, A.J.; Grunberger, G.; Guerin, C.K.; Bell, D.S. and Mechanick, J.I. (2017). American Association of Clinical Endocrinologists and American College of Endocrinology guidelines for management of dyslipidemia and prevention of cardiovascular disease. *Endocrine Practice*, 23: 1-87.
- Joda, M. (2008). *The progressive statistical analysis by using SPSS 1st ed.* Wales house editions, Amman Jordan.w.
- Twegh, Moaid .Abd-Elsahib.; Karrar Jasim Hamzah.; Adnan Mansour Jasim and Qassim Abbas Mohammed (2020). Protective role of vitamin-tpgs to overcome oxidative stress induced by dipping of sheep with cypermethrin. *Plant Archives*, 20(1): 1105-1109.
- Lacolley, P.; Regnault, V.; Segers, P. and Laurent, S. (2017). Vascular smooth muscle cells and arterial stiffening: relevance in development, aging, and disease. *Physiological reviews*, 97: 1555-1617.
- Lee, D. Y.; Li, H.; Lim, H. J.; Lee, H. J.; Jeon, R. and Ryu, J.H. (2012). Anti-inflammatory activity of sulfur-containing compounds from garlic. *Journal of medicinal food*, 15(11): 992-999.
- Makris, A.; Thornton, C.E.; Xu, B. and Hennessy, A. (2005). Garlic increases IL-10 and inhibits TNF α and IL-6 production in endotoxin-stimulated human placental explants. *Placenta*, 26(10): 828-834.
- Miao, Q.; Wang, R.; Bai, D.; Xue, X.; Xu, J.; Sun, X.; & Liu, L. (2020). Antiatherosclerosis Properties of Total Saponins of Garlic in Rats. *Evidence-Based Complementary and Alternative Medicine*, 2020.
- Mihaylova, B.; Schlackow, I.; Herrington, W.; Lozano-Kühne, J.; Kent, S.; Emberson, J.; Reith, C.; Haynes, R.; Cass, A. and Craig, J. (2016). Cost-effectiveness of simvastatin plus ezetimibe for cardiovascular prevention in CKD: results of the Study of Heart and Renal Protection (SHARP). *American Journal of Kidney Diseases*, 67: 576-584.
- Mozaffarian, D.; Benjamin, E. J.; GO, A.S.; Arnett, D.K.; Blaha, M. J.; Cushman, M.; Das, S. R.; DE Ferranti, S.; Després, J.P. and Fullerton, H.J. (2016). Executive summary: heart disease and stroke statistics-2016 update: a report from the American Heart Association. *Circulation*, 133: 447-454.
- Olschewski, H.; Rose, F.; Schermuly, R.; Ghofrani, H.A.; Enke, B.; Olschewski, A.; & Seeger, W. (2004). Prostacyclin and its analogues in the treatment of pulmonary hypertension. *Pharmacology & therapeutics*, 102(2): 139-153.
- Pashaie, B.; Hobbenaghi, R.; and Malekinejad, H. (2017). Anti-atherosclerotic effect of *Cynodon dactylon* extract on experimentally induced hypercholesterolemia in rats. In *Veterinary Research Forum* (Vol. 8, No. 3, p. 185). Faculty of Veterinary Medicine, Urmia University, Urmia, Iran.
- Prahalathan, P.; Saravanakumar, M.; and Raja, B. (2012). The flavonoid morin restores blood pressure and lipid metabolism in DOCA-salt hypertensive rats. *Redox Report*, 17(4): 167-175.
- Rosa, C. de O. B.; Dos Santos, C. A.; Leite, J.I.A.; Caldas, A.P.S. and Bressan, J. (2015). Impact of nutrients and food components on dyslipidemias: what is the evidence? *Advances in Nutrition*, 6(6): 703-711.
- Sabat, R.; Grütz, G.; Warszawska, K.; Kirsch, S.; Witte, E.; Wolk, K. and Geginat, J. (2010). Biology of interleukin-10. *Cytokine & growth factor reviews*, 21(5): 331-344.
- Singh, A.K. (2017). Comparative therapeutic effects of plant-extract synthesized and traditionally synthesized gold nanoparticles on alcohol-induced inflammatory activity in sh-sy5y cells in vitro. *Biomedicines*, 5(4): 70.
- Singh, D. and Chaudhuri, P.K. (2018). Structural characteristics, bioavailability and cardioprotective potential of saponins. *Integrative medicine research*, 7(1): 33-43.
- Torzewski, M.; Waqar, A.B. and Fan, J. (2014). *Animal models of C-reactive protein. Mediators of inflammation*, 2014.
- Worrall, E.A.; Hamid, A.; Mody, K.T.; Mitter, N. and Pappu, H.R. (2018). Nanotechnology for plant disease management. *Agronomy*, 8(12): 285.
- Zare, E.; Alirezaei, A.; Bakhtiyari, M.; & Mansouri, A. (2019). Evaluating the effect of garlic extract on serum inflammatory markers of peritoneal dialysis patients: a randomized double-blind clinical trial study. *BMC nephrology*, 20(1): 26.
- Zhang, M.; Viennois, E.; Prasad, M.; Zhang, Y.; Wang, L.; Zhang, Z.; Han, M. K.; Xiao, B.; Xu, C. & Srinivasan, S. (2016). Edible ginger-derived nanoparticles: A novel therapeutic approach for the prevention and treatment of inflammatory bowel disease and colitis-associated cancer. *Biomaterials*, 101: 321-340.